

Covid-19 Associated Mucormycosis: A Case Report

Oshan Shrestha,¹ Reetu Sharma Baral¹

ABSTRACT

One of the most common complication of Coronavirus disease 2019 (COVID-19) is acute respiratory distress syndrome requiring high flow oxygen, ventilator support, corticosteroids and other supportive therapies. Opportunistic aggressive fungal infection with Mucormycosis, although an uncommon entity otherwise, has been on rise in this pandemic especially in patients with chronic underlying illnesses. One such case of rhino-orbital Mucormycosis in a background of uncontrolled hyperglycaemia presented in the hospital and the histopathological examination of the tissues from ethmoidal sinus and frontal recess showed invasive necro-inflammatory infection by numerous Mucormycosis hyphae.

Keywords: COVID-19; mucormycosis; rhino-orbital

INTRODUCTION

Corona virus disease 2019 (COVID-19) pandemic has claimed over 3.7 million lives worldwide and the figure grows every day.¹ Systemic glucocorticoids have shown to improve survival in patients developing severe respiratory symptoms in such patients.² Although invasive pulmonary Aspergillosis complicating the disease course is widely known, cases of Mucormycosis are limited.³ They pose a specific threat owing to their highly aggressive and angioinvasive behaviour. Prompt diagnosis and management of the infection is thus mandatory. Herein, we report one such case of rhino-orbital Mucormycosis in a COVID-19 patient diagnosed on histopathological grounds.

CASE REPORT

Multiple bits of biopsy specimen of a 44 years old woman who had undergone tissue debridement from right frontal recess, middle turbinate and ethmoidal sinus for the clinical suspicion of Mucormycosis was received from the Department of ENT. On clinical document review she had uncontrolled type 2 diabetes mellitus for last 18 years under Metformin 500mg/day. She developed mild fever and cough for 3 days, then she tested positive on RT-PCR for COVID-19. Oxygen saturation dropped below 90% and chest X-ray showed bilateral diffuse interstitial opacities. She was then started on oral glucocorticoids (Dexamethasone 12 mg/day) for a week. The fasting blood sugar level and HbA1c performed 2 days later was 340mg/dl and 13.6% respectively and thus she was kept on Insulin 20 units a day. Repeat RTPCR for COVID-19 came negative after 2 weeks and discharged

from hospital. She however developed swelling and mild pain in the right orbital region, 2 days after the negative RTPCR report. On follow up in the same hospital, urine acetone test was positive and the fasting blood sugar was still 296mg/dl. Computed tomography (CT) of head and neck showed features of sinusitis in right maxillary, ethmoidal and sphenoidal sinuses. She was initially managed symptomatically but there was no improvement. Then only she came to this hospital on fourth day of orbital swelling.

The KOH preparation showed plenty of branched aseptate fungal elements. Histopathological reporting was done on the 3rd post-operative day and it revealed large areas of dirty necrosis with some dead bony fragments. Higher magnification showed numerous broad, foldable, aseptate, right angle branching hyphal forms of fungal organisms corresponding to the morphology of Mucormycosis. These fungal organisms invaded the underlying stroma and blood vessels (Figure 1).

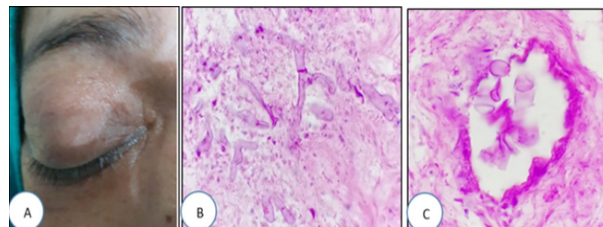


Figure 1. Right orbital swelling (A); multiple broad, ribbon like aseptate hyphae of Mucormycosis in necro-inflammatory background (B); and angioinvasion by hyphal forms (C).

Correspondence: Dr Oshan Shrestha, Nobel Medical College and Teaching Hospital, Kathmandu University, Biratnagar, Nepal. Email: oshanpgi@gmail.com, Phone: +9779841701161.

The CRP and the D-dimer level were elevated to 95.7 mg/l and 1.75 mg/l respectively. Complete blood count, electrolytes, renal function tests, liver function tests and prothrombin time were all normal.

DISCUSSION

Beneficiary role, easy availability and affordability has led to its frequent use of glucocorticoids in COVID-19 patients with severe respiratory illness.² However, it increases the susceptibility to opportunistic infections especially in patients with underlying chronic co-morbid conditions. Immune dysregulation caused by the virus itself, nosocomial infection and immunomodulatory drugs may cause opportunistic infections.⁴ Previous studies have shown that patients with Influenza and COVID-19 pneumonia are at increased risk of invasive pulmonary Aspergillosis and Candidiasis.^{5,6} Mucormycosis on the other hand, remains largely unrecognized. No biochemical markers, imaging picture or clinical presentations are specific for the infection; and thus there is generally a low degree of clinical suspicion. Diabetes mellitus is a major risk factor for Mucormycosis and these patients fare a much worse prognosis than others.⁷ Control of hyperglycaemia, early diagnosis and treatment with liposomal Amphotericin B and complete surgical debridement are essential to manage these cases effectively.⁸

Mucormycosis has shown predilection to specific sites depending in the underlying pathology. Diabetic usually show rhino-orbital-cerebral Mucormycosis while patients with severe neutropenia and graft-vs-host disease develop pulmonary Mucormycosis.⁹ Our patient had COVID-19 infection with uncontrolled hyperglycaemia and was on oral dexamethasone 12 mg per day. She developed diabetic ketoacidosis followed by right sided rhino-orbital Mucormycosis. Definite diagnosis of Mucormycosis requires both microbiological and histological evidence.¹⁰ Studies have shown that formalin-fixed-paraffin-embedding processing techniques used in histopathology may inactivate the virus; and is thus the histopathology would be better in the context of infection prevention and control.^{11,12} Moreover, fungal isolation and culture aren't readily available in many resource constraint settings and histopathological identification of the organism can be a safe diagnostic modality in such instances. To the best of our knowledge, this is the first report of an invasive rhino-orbital Mucormycosis in a COVID-19 patient from Nepal and only the third globally. This case highlights uncontrolled hyperglycaemia as a risk factor and establishes the role of histopathological examination in early definite diagnosis of Mucormycosis.

CONCLUSIONS

Histopathological examination of the tissue sample can serve as a prompt, safe and highly reliable diagnostic modality for Mucormycosis that will help in early management of this highly aggressive fungal infection. Angio-invasion was also identified in this case. Physicians must have a high degree of suspicion for opportunistic infections that can complicate COVID-19 patients especially with risk factors like diabetes.

Author Affiliations

¹Department of Pathology, Nobel Medical College and Teaching Hospital, Kathmandu University, Biratnagar, Nepal

Competing interests: None declared

REFERENCES

1. COVID Live Update: 172,505,361 Cases and 3,708,463 Deaths from the Coronavirus - Worldometer [Internet]. [cited 2021 Jun 3]. <https://www.worldometers.info/coronavirus/>
2. Sterne JA, Murthy S, Diaz JV, Slutsky AS, Villar J, Angus DC, et al. Association between administration of systemic corticosteroids and mortality among critically ill patients with COVID-19: a meta-analysis. *Jama*. 2020 Oct 6;324(13):1330-41. [[DownloadPDF](#)]
3. Arastehfar A, Carvalho A, Van De Veerdonk FL, Jenks JD, Koehler P, Krause R, et al. COVID-19 associated pulmonary aspergillosis (CAPA)—from immunology to treatment. *Journal of Fungi*. 2020 Jun;6(2):91.
4. Kimmig LM, Wu D, Gold M, Pettit NN, Pitrak D, Mueller J, et al. Il-6 inhibition in critically ill COVID-19 patients is associated with increased secondary infections. *Frontiers in medicine*. 2020 Oct 28;7:689. [[FullTextLink](#)]
5. Salehi M, Ahmadikia K, Mahmoudi S, Kalantari S, Jamalimoghadasiahkali S, Izadi A, et al. Oropharyngeal candidiasis in hospitalised COVID-19 patients from Iran: Species identification and antifungal susceptibility pattern. *Mycoses*. 2020 Aug;63(8):771-8. [[Article](#)]
6. Alanio A, Dellièrè S, Fodil S, Bretagne S, Mégarbane B. Prevalence of putative invasive pulmonary aspergillosis in critically ill patients with COVID-19. *The Lancet Respiratory Medicine*. 2020 Jun 1;8(6):e48-9. [[DownloadPDF](#)]
7. Apicella M, Campopiano MC, Mantuano M, Mazoni L, Coppelli A, Prato SD. COVID-19 in people with diabetes: understanding the reasons for worse outcomes. *Lancet Diabetes Endocrinol*. 2020 Sep 1;8(9):782–92.

8. Cornely OA, Alastruey-Izquierdo A, Arenz D, Chen SC, Dannaoui E, Hochhegger B, et al. Global guideline for the diagnosis and management of mucormycosis: an initiative of the European Confederation of Medical Mycology in cooperation with the Mycoses Study Group Education and Research Consortium. *The Lancet infectious diseases*. 2019 Dec 1;19(12):e405-21.
9. Vandroux D, Allyn J, Ferdynus C, Gaüzere B-A, Kerambrun H, Galas T, et al. Mortality of critically ill patients with severe influenza starting four years after the 2009 pandemic. *Infect Dis Lond Engl*. 2019 Dec;51(11-12):831-7. [\[Article\]](#)
10. Skiada A, Lass-Floerl C, Klimko N, Ibrahim A, Roilides E, Petrikos G. Challenges in the diagnosis and treatment of mucormycosis. *Med Mycol*. 2018 Apr;56(Suppl 1):S93-101. [\[Article\]](#)
11. Iwen PC, Stiles KL, Pentella MA. Safety Considerations in the Laboratory Testing of Specimens Suspected or Known to Contain the Severe Acute Respiratory Syndrome Coronavirus 2 (SARS-CoV-2). *Am J Clin Pathol*. 2020 Apr 15;153(5):567-70. [\[Article\]](#)
12. Henwood AF. Coronavirus disinfection in histopathology. *J Histotechnol*. 2020 Jun;43(2):102-4. [\[Article\]](#)