

# Clinical and histopathological presentation of abnormal uterine bleeding in perimenopausal women in tertiary center of Nepal

Sadikchha Chapagain,<sup>1</sup> Ganesh Dangal<sup>2</sup>

<sup>1</sup>Department of Obstetrics and Gynecology, Paropakar Maternity and Women's Hospital, Kathmandu, Nepal,

<sup>2</sup>Department of Obstetrics and Gynecology, Kathmandu Model Hospital, Nepal.

## ABSTRACT

**Background:** Abnormal uterine bleeding is defined as any bleeding outside of normal menstruation pattern with excessive duration, frequency, and amount and it is a common problem among women of reproductive age group with varied presentations. The aim of the study was to correlate the histopathological finding in patients with abnormal dysfunctional uterine bleeding with the presenting clinical feature.

**Methods:** A prospective cross sectional study was carried out at Paropakar Maternity and Women's Hospital, Thapathali, Kathmandu during the period of one year (February 2019 to January 2020). It included 77 perimenopausal women with abnormal uterine bleeding who presented in gynecology outpatient department and planned for dilatation and curettage. Then the participants were counselled and informed consent was taken. Histopathological reports reviewed and analysis done.

**Results:** The most common age group of women presenting with abnormal uterine bleeding was 40 to 44 years and the commonest clinical feature was menorrhagia (31/77, 40.3%) followed by menometrorrhagia (18/77, 23.4%). Majority of women were multiparous, parity 3 to 4 (38/77, 49.4%). Proliferative endometrium (29/77, 37.7%) was most common histopathological findings followed by secretory endometrium (24/77, 31.2%). Proliferative endometrium was more commonly associated with menorrhagia and menometrorrhagia whereas secretory endometrium with metrorrhagia (P-value 0.000).

**Conclusions:** Menorrhagia and Menometrorrhagia are the most common clinical presentation among perimenopausal women with AUB, whereas proliferative endometrium and secretory endometrium were the common histopathological findings respectively. Accurate diagnosis is crucial for a selection of relevant treatment and avoidance of unnecessary major surgical procedure.

**Keywords:** Abnormal uterine bleeding; endometrium; histopathology; perimenopausal.

## INTRODUCTION

For the consistent understanding of abnormal uterine bleeding (AUB), the normal and abnormal pattern has been described. The criteria for normal menstruation comprises of 21-35 days cycle with 2-7 days flow and 30-80ml of total blood loss in a single menstrual cycle. Thus, the bleeding other than this is considered as Abnormal Uterine Bleeding.<sup>1</sup>

AUB, a term used to describe any type of bleeding that does not fall within the normal ranges for amount, frequency, duration or cyclicity. The most common presentations are menorrhagia, polymenorrhoea,

metrorrhagia, and intermenstrual bleeding.<sup>2</sup> AUB accounts for 33% of outpatient referrals.<sup>3</sup> In women  $\geq$  40 years, it mandates evaluation to confirm benign nature of the problem by ruling out endometrial carcinoma, so that conservative treatment can be offered and unnecessary radical surgery can be avoided.<sup>1-4</sup>

There are various methods to diagnose the cause of AUB- ultrasonography, transvaginal sonography, dilatation and curettage (D and C) and hysteroscopy.<sup>5,6</sup> The common pathologies detected histologically in AUB include hormonal imbalance pattern, atrophic endometrium, endometritis, endometrial hyperplasia and endometrial carcinoma.<sup>7,8</sup>

**Correspondence:** Dr Sadikchha Chapagain, Department of Obstetrics and Gynecology, Paropakar Maternity and Women's Hospital, Kathmandu, Nepal, Email: [saddysharma2468@gmail.com](mailto:saddysharma2468@gmail.com), Phone: +977 9847071232.

The aim of the study was to correlate the histopathological finding in patients with abnormal dysfunctional uterine bleeding with the presenting clinical feature

**METHODS**

This is a prospective cross-sectional study conducted at Paropakar Maternity and Women’s Hospital (PMWH), Thapathali, Kathmandu, Nepal from February 2019 to January 2020. Inclusion criteria included all women in perimenopausal age (40-54 years) with any parity with abnormal uterine bleeding. Women with known coagulopathy, genital malignancy, under hormonal therapy, fibroid uterus and intrauterine devices were excluded from the study.

All patients included in this study were informed about the study and its objectives. Written informed consent was taken. Privacy and confidentiality was maintained. Written permission was obtained from IRC of NAMS (National Academy of Medical Sciences and PMWH (Paropakar Maternity and Womens Hospital).

All of the enrolled cases were subjected to endometrial sampling. Sequentially the results of histopathology obtained. Age incidence, clinical presentation, histopathological findings, the correlation between clinical presentation (Menorrhagia, Menometrorrhagia, Metrorrhagia, Oligomenorrhoea, Polymenorrhoea, and intermenstrual bleeding) and histopathological findings (Proliferative endometrium, Secretory endometrium, Atrophic endometrium, simple and complex endometrial hyperplasia with or without atypia, and Endometrial carcinoma) were evaluated.

All data were analyzed manually and with the help of SPSS version 23 and comparison of variables was done.

**RESULTS**

A total of 77 women presented with abnormal uterine bleeding underwent endometrial sampling and sent for HPE. Clinical presentations and histopathological reports were correlated. Majority of the women were between 40 to 44 years (35/77, 45.5%). Least common age group were between 50 to 54 years (18/77, 23.4%) (Figure-1). Menorrhagia 40.3% was the commonest presenting symptoms followed by Menometrorrhagia 23.4% (Table-1). Twenty nine cases (37.7%) were reported to have endometrium showing proliferative features in histopathology, followed by secretory endometrium,

31.2% and hyperplastic endometrium, 15.6% (Table.2). Majority of women had no any co-morbidity. Proliferative endometriums were significantly more found in patients with menorrhagia symptom followed by menometrorrhagia (P-value 0.000). The most common histopathological finding was secretory endometrium in patients with metrorrhagia and polymenorrhoea symptom. Endometrial carcinoma and chronic endometritis were observed in endometrial specimens of patients with the complaint of intermenstrual bleeding (Table 3).

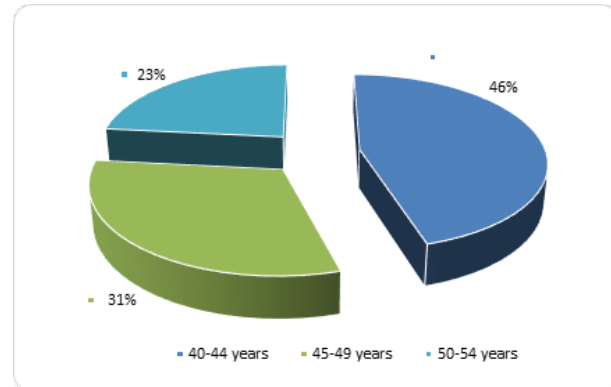


Figure 1. Age distribution.

Table 1. Clinical features of AUB (n=77).

Bleeding pattern	Frequency	Percent
Menorrhagia	31	40.3
Polymenorrhoea	10	13
Oligomenorrhoea	5	6.5
Metrorrhagia	11	14.3
Menometrorrhagia	18	23.4
Intermenstrual bleeding	2	2.6

Table 2. Distribution of histopathological findings (n=77).

Histopathological Findings	Frequency	Percent
Secretory endometrium	24	31.1
Proliferative endometrium	29	37.7
Atrophic endometrium	4	5.2
Hyperplastic Endometrium	12	15.6
Complex Endometrial Hyperplasia without Atypia	2	2.6
Simple Endometrial Hyperplasia without Atypia	1	1.3
Endometrial carcinoma	2	2.6
Endometritis	3	3.9

**Table 3. Endometrial pattern in various types of clinical features (n=77).**

Histopathological Findings	Menorrhagia	Polymenorrhea	Oligomenorrhoea	Metorrhagia	Menometrorrhagia	Intermenstrual bleeding	Total
Atrophic endometrium	-	2	2	-	-	-	4
Complex endometrial hyperplasia without atypia	1	-	-	-	1	-	2
Endometrial carcinoma	1	-	-	-	-	1	2
Endometritis	-	2	-	-	-	1	3
Hyperplastic Endometrium	5	1	-	-	6	-	12
Proliferative endometrium	18	-	-	3	8	-	29
Secretory endometrium	5	5	3	8	3	-	24
Simple endometrial hyperplasia without atypia	1	-	-	-	-	-	1
<b>Total</b>	<b>30</b>	<b>10</b>	<b>5</b>	<b>11</b>	<b>18</b>	<b>3</b>	<b>77</b>

**DISCUSSION**

Abnormal Uterine Bleeding (AUB) is a common problem among women of perimenopausal age group with varied presentations. AUB can be caused by a wide variety of disorders. Because of its broad range of differential diagnosis, diagnosis of AUB is quite challenging: despite detailed history, various blood test and thorough pelvic examination often involving ultrasonography, the cause of bleeding established in only 50-60% of cases.<sup>5</sup>

Endometrial pathologies as polyps, submucous myomas, endometrial hyperplasia, and endometrial carcinoma must be suspected and evaluation of endometrium is necessary in AUB in perimenopausal women.<sup>6</sup> Endometrial biopsy or Dilatation and Curettage (D & C) is a safe and effective technique for evaluation of AUB and diagnosis of endometrial pathologies such as infections, polyps, endometrial hyperplasia and, endometrial carcinoma.<sup>9</sup> AUB is a general term and can have a broad range of clinical features such as oligomenorrhoea, polymenorrhoea, menorrhagia, menometrorrhagia, metrorrhagia, mid-cycle spotting and, abnormal acute vaginal bleeding and the patient can come to the clinic

with a variety of abnormal bleeding pattern.<sup>10</sup>

The incidence of AUB was 30 to 70% according to study conducted by Jaiswar,<sup>11</sup> Firdous et al<sup>9</sup> and Chaudhary.<sup>12</sup> The study conducted by Sharma et al<sup>13</sup> was similar to the study conducted by Mishra et al<sup>14</sup> which was 30%. According to Shrestha,<sup>15</sup> it was 27.59% which is a bit lower than other studies. In our study, it is much lower 4.8% in Paropakar maternity and women hospital in year 2017 even lower than study conducted by Kumar<sup>16</sup> which was 9 to 14%

The mean age of patients presented with AUB were 45 years (range 41-50) in the study conducted by Valson.<sup>17</sup> Similar findings were there according to Shrestha<sup>15</sup> 41 to 45 years (47%), Kumar et al<sup>16</sup> 31 to 50 years (68%) and Bhatiyani et al.<sup>18</sup> Mahapatra<sup>19</sup> and Mishra et al<sup>14</sup> found similar findings as the common age group to be 41 to 45 years (37%).

In our study, majority of women with AUB were between age group 40 to 44 years (45.5%) followed by 45 to 49 years (37.5%) which were similar to study by Valson<sup>17</sup> and Bhatiyani et al.<sup>18</sup> Least common age group was 50 to 54 years (18%). The reason for the increased incidence of abnormal uterine bleeding in this age group (40 to 50 years) may be because of the fact that these patients were in their climacteric period. As women approach menopause, cycles shorten and often become intermittently anovulatory due to the decline in the number of ovarian follicles and estradiol level.<sup>17,18</sup> The incidence of AUB above 50 years was lower compared to those between 46 to 50 years. The reason for this finding may be due to the fact that patients were evaluated much earlier and treated appropriately, thereby decreasing the incidence in the later age group.

In AUB, most common presenting complaints were menorrhagia (39.79%) followed by metrorrhagia (30%) according to study conducted by Chaudhary.<sup>12</sup> Findings were similar in study conducted by Razzaq et al<sup>20</sup> and Shrestha.<sup>15</sup> This similar finding in this study may be due to similar socio-economic status, environment and race.

In our study, most common presentation in women with AUB was menorrhagia (40.3%), menometrorrhagia (23.4%), metrorrhagia (14.3%), polymenorrhoea (13%), oligomenorrhoea (6.5%) and intermenstrual Bleeding (2.6%). Similar incidence of presenting complaints were found in study conducted by Jaiswar,<sup>11</sup> Valson,<sup>17</sup> Singh,<sup>21</sup> Mishra<sup>14</sup> and Kathuria et al.<sup>22</sup> In contrast, only one study conducted by Abidet al<sup>23</sup> showed polymenorrhoea as the commonest presenting complaints.

Study by Das et al<sup>24</sup> showed various histological patterns of which predominant pattern seen was of normal cyclical

endometrium (proliferative and secretory phases) and was seen in 106 (46.1%) cases. Similar findings were seen in the study conducted by Razzaq et al<sup>20</sup>, Bhatiyani<sup>18</sup>, Shrestha<sup>15</sup> and Singh et al.<sup>21</sup> On contrary, the study by Mishra et al<sup>14</sup> showed endometrial atrophy (45.2%) to be most common pattern.

In our study proliferative endometrium (37.7%) was most common histopathological findings as in most of the study followed by secretory endometrium (31.2%), hyperplastic endometrium (15.6%), atrophic endometrium (5.2%), endometritis (3.9%), endometrial carcinoma (3.3%), complex endometrial hyperplasia without atypia (2.6%) and simple endometrial hyperplasia without atypia (1.3%). Similar to our study proliferative endometrium was most common histopathological findings in study of Vani et al,<sup>25</sup> Mahapatra<sup>19</sup> and Sajitha et al.<sup>26</sup> In our study, hyperplastic endometrium was 3<sup>rd</sup> most common finding which was least common in study of Chaudhary<sup>12</sup>, Kumar et al,<sup>16</sup> Kathuria et al<sup>22</sup> and Valson.<sup>17</sup>

In our study, 2.6 % of endometrial carcinoma was found which was very less in comparison to the study conducted by Kumar<sup>16</sup> (4 %). In our study proliferative endometrium was more commonly associated with symptom menorrhagia and metrorrhagia whereas secretory endometrium with metrorrhagia with p-value of 0.000 which is statistically significant similar to the study done by Yilmaz et al<sup>27</sup> in the year 2015 in 313 cases of AUB in perimenopausal women.

The study population was hospital based and therefore sample size might not be representative for entire population. The study was carried out in a small sample for a short duration of time. The study was done on selected age group of women. Thus, these findings may not be applicable to all.

## CONCLUSIONS

Menorrhagia and metrorrhagia are the most common clinical presentation among perimenopausal women with AUB, whereas proliferative endometrium and secretory endometrium were the common histopathological findings respectively.

## REFERENCES

1. Goldenstein SR. Modern evaluation of endometrium. *Obstet Gynecol.* 2010;116(1):168-76. [\[PubMed\]](#)
2. Oehler MK, Rees MC. Menorrhagoa: an update. *Acta Obstet Gynecol Scand.* 2003;82(5):404-22. [\[PubMed\]](#)
3. Mencoglia L, Perino A, Hamou J. Hysteroscopy in perimenopausal and post-menopausal women with abnormal uterine bleeding. *J Reprod Med.*

- 1987;32(8):577-82. [\[PubMed\]](#)
4. Chambers JT, Chambers SK. Endometrial sampling: When? Where? Why? With what? *Clin Obstet Gynecol.* 1992;35(1):28-39. [\[PubMed\]](#)
5. Spencer CP, Whitehead MI. Endometrial assessment revisited. *B J Obset Gynecol.* 1999;106(7):623-32. [\[PubMed\]](#)
6. Chabra S, Jaswal M, Nangia V. Uterine size, endometrium, fertility in women with dysfunctional uterine bleeding. *J ObstetGynaecol India.* 1998; 42:623-32. [\[FullText\]](#)
7. Anastasiadis PG, Skaphida PG, Koutlaki NG, Galazios GC, Tsikouras PN, Liberis VA. Descriptive epidemiology of endometrial hyperplasia in patients with abnormal uterine bleeding. *Eur J Gynaecol Oncol.* 2000;21(2):131-4. [\[PubMed\]](#)
8. Longacre T, Atkins K, Kempson R, Hendrickson M. The uterine corpus. In Sternberg's *Diagnostic Surgical Pathology*, 5th Edition. Newyork: Lippincott William & Wilkins;2009:2184–2277.
9. Firdous N, Mukhtar S, Bilal S, Beigh SK. Role of hysteroscopy and histopathology in evaluating patients with abnormal uterine bleeding. *Int J Reprod Contracept Obstet Gynecol.* 2017;6(2):615-19. [\[Link\]](#)
10. Hoffman B, Schorge J, Bradshaw K, Holvorson L, Schaffer J, Corton M. Williams *Gynecology*, 3<sup>rd</sup> edition. Newyork: Mcgraw hill education; 2016.
11. Jaiswar SP, Sachan R, Srivastava PK, Goel M, Pandey M. A comparative diagnostic evaluation of hysteroscopy, transvaginalsonography and histopathological examination in cases of abnormal uterine bleeding. *J. Obstet Gynaecol.* 2006;56(3):240-3. [\[FullText\]](#)
12. Chaudhari KR, Sathe P. Role of diagnostic hysteroscopy in evaluation of abnormal uterine bleeding and its histopathological correlation. *Int J Reprod Contracept Obstet Gynecol.* 2014;3(3):666-70. [\[Link\]](#)
13. Sharma J, Tiwari S. Hysteroscopy in abnormal uterine bleeding vs ultrasonography and histopathology report in perimenopausal and postmenopausal women. *J Nepal Med Assoc.* 2016;55(203):26-8. [\[PubMed\]](#)
14. Mishra S, Panda B. Efficacy of ultrasonography and hysteroscopy and their correlation with endometrial histopathology in a case of abnormal uterine bleeding in late reproductive age. *Ann Int Med Den Res.* 2018;4(5):10-4. [\[FullText\]](#)
15. Shrestha A, Kayastha B, Makaju R. Diagnostic

- hysteroscopy in abnormal uterine bleeding: a five years study in Kathmandu university hospital. *Int J Sci Rep* 2017;3(5):128-33. <http://dx.doi.org/10.18203/issn.2454-2156.IntJSciRep20171998>
16. Kumar A, Sathya P, Sampathkumar S. Study of hysteroscopic evaluation in patients with abnormal uterine bleeding. *Int J Reprod Contracept Obstet Gynecol.* 2017;6(4):1413-9. <http://dx.doi.org/10.18203/2320-1770.ijrcog20171401>
17. Valson H, Kulkarni C, Mukerjee S, Gowda SN. The role of diagnostic hysteroscopy in abnormal uterine bleeding and its histopathological correlation following blind dilatation and curettage. *Int J Reprod Contracept Obstet Gynecol.* 2016;5: 609-14. [\[FullText\]](#)
18. Bhatiyani BR, Dhumale S, Pandeewari, Bashani D. Correlation between ultrasonographic, hysteroscopic and histopathological findings in patients with abnormal uterine bleeding. *Int J Reprod Contracept Obstet Gynecol.* 2018;7(8):3250-6. <http://dx.doi.org/10.18203/2320-1770.ijrcog20183326>
19. Mahapatra M, Mishra P. Clinicopathological evaluation of abnormal uterine bleeding. *J Health Res Rev.* 2015;2(2):45-9. [\[Link\]](#)
20. Razzaq A, Shukar-ud-Din S, Soomro N. Role of diagnostic hysteroscopy in case of abnormal uterine bleeding. *Pak J Surg.* 2011;27(4): 309-15. [\[FullText\]](#)
21. Singh A, Bai RPV. Study of histopathological pattern of endometrium in abnormal uterine bleeding and its management. *Int J Reprod Contracept Obstet Gynecol.* 2016;5(2):432-6. <http://dx.doi.org/10.18203/2320-1770.ijrcog20160384>
22. Kathuria R, Bhatnagar B. Correlation between D and C, USG and hysteroscopy findings in diagnosing a case for abnormal uterine bleeding. *Indian Journal of Clinical Practice.* 2014; 2 (5):466-470. [\[FullText\]](#)
23. Abid M, Atif Ali H, Babar M, Saroona H, Naveen F, Edhi MM, et al. Clinical pattern and spectrum of endometrial pathologies in patients with abnormal uterine bleeding in Pakistan: need to adopt a more conservative approach to treatment. *BMC Women's Health.* 2014;14: 132. [\[Link\]](#)
24. Das B, Das A. Histopathological patterns of endometrial biopsy in abnormal uterine bleeding. *Indian Journal of Applied Research.* 2016;6(6):539-41. [\[Link\]](#)
25. Padmaja GJV, Quadri SSS, Kumar OS. Histomorphological profile of endometrium in perimenopausal bleeding. *IAIM.* 2016;3(7):255-9. [\[FullText\]](#)
26. Sajitha K, Shetty P, Shetty J, Prasad HLK, Permi HS, Hegde P. Study of histopathological patterns of endometrium in abnormal uterine bleeding. *CHRISHMED Journal of Health and Research.* 2014;1(2):76-80. [\[Link\]](#)
27. Yilmaz Z, Elif A, Bulent C, Ismail G, Mehmet K, Yasemin C, et al. Correlation of bleeding pattern with endometrial histopathologic results in perimenopausal women with abnormal uterine bleeding. *Int J Reprod Contracept Obstet Gynecol.* 2015 ;4(3):1-4. <http://dx.doi.org/10.18203/2320-1770.ijrcog20150001>