

# Assessment of Knee Joint Injuries with Low Field Strength Magnetic Resonance Imaging

Panta OB,<sup>1</sup> Neupane NP,<sup>1</sup> Songmen S,<sup>1</sup> Gurung G<sup>1</sup>

<sup>1</sup>Department of Radiology and imaging, Tribhuvan University Teaching Hospital, Maharajgunj, Kathmandu, Nepal.

## ABSTRACT

**Background:** Magnetic Resonance Imaging is an appropriate screening tool before therapeutic arthroscopy, making diagnostic arthroscopy unnecessary in most patients. This study aims to evaluate the MRI findings in knee injuries and diagnostic value of low Strength MRI for assessing Meniscal and cruciate ligament tear.

**Methods:** A cross sectional study was conducted on patients undergoing “Magnetic Resonance Imaging of the Knee” for injuries of the knee and excluded patients undergoing MRI for other causes, poor diagnostic quality MRI and post operative MRI. All patients were interviewed for mechanism of injury and followed up for arthroscopic findings. Statistical analysis was done using IBM SPSS 20.0.

**Results:** A total of 81 MRIs was included in the study. Arthroscopic finding of only 32 patients could be followed up. Anterior cruciate ligament (ACL) tear was the most common internal ligament tear accounting for 34(42%) of cases followed by medial meniscus tear in 33(40.7%). Twisting 14( 42.4%) was the most common mechanism involved in medial meniscus tear while combined mechanism of injury was most common mechanism for ACL tear 16( 47.05%). The sensitivity of MRI for diagnosis of ACL tear and medial meniscus tear was 96.3% and 94.7% respectively. Specificity for ACL tear was however only 80% and that for medial meniscus tear was 100%.

**Conclusions:** The diagnostic value of MRI for diagnosing internal derangement of knee was high even with a low Tesla (0.3 T) MRI thus emphasizing the role of MRI as a non-invasive alternative to diagnostic arthroscopy.

**Keywords:** ACL tear; knee Joint injuries; magnetic resonance imaging; medial meniscus tear.

## INTRODUCTION

Internal injuries of knee joint accounts for almost half of all sports injury.<sup>1</sup> Physical examinations techniques used in assessment of internal knee injuries has many limitations and lacks sufficient sensitivity and specificity to be used solely as a diagnostic tool. Invasive procedures like arthroscopy and arthrotomy are the gold standards for the diagnosis of internal knee injuries however they are criticized for their invasive nature, highly skilled operator requirement and their high cost. MRI represents the optimal imaging tool in the evaluation of the sports related knee injuries, which has been shown to be an accurate and non invasive method of diagnosing ligament, meniscal, cartilage and

muscular knee injuries.<sup>2</sup> MR imaging is an appropriate screening tool before therapeutic arthroscopy, making diagnostic arthroscopy unnecessary in most patients.<sup>3</sup> Due to economic constrains in countries like Nepal, high magnetic field strength MRI has limited availability and low field strength equipment are used in most centers. This study aimed to review MRI findings in knee joint injuries; identify the mechanism of injury and evaluate diagnostic value of low Strength MRI for assessing Meniscal and cruciate ligament tear.

## METHODS

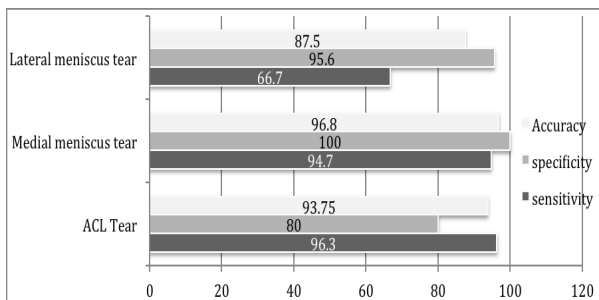
This was a hospital based cross sectional study. The study was included patients undergoing “Magnetic

**Correspondence:** Dr Om Biju Panta, Department of Radiology and imaging, Tribhuvan University Teaching Hospital, Maharajgunj, Kathmandu, Nepal. Email: bijupanta@yahoo.com, Phone: +9779842877382.

Resonance Imaging of the Knee” for injuries of the knee during the study period: August 2013 to July 2014 in Department of Radiology and imaging, Tribhuvan University Teaching Hospital . The ethical clearance was obtained from the institutional review board, Institute of Medicine. Informed consent was taken from patients for inclusion in the study. Patients undergoing MRI for reasons other than trauma; postoperative cases and motion or other artifacts in the MRI that significantly altered imaging evaluation were excluded from the study. All knee MRI were performed using Hitachi Airis Vento 0.3 T permanent magnet MRI machine. Patients were interviewed for mechanism of injuries and followed up for arthroscopies. Only arthroscopies performed in our center were included in the study for correlation. Statistical analysis was performed using IBM SPSS 20.0. Sensitivity, specificity, positive and negative predictive value for MRI in diagnosing cruciate ligaments and meniscal tear was calculated.

**RESULTS**

A total of 81 MRI, which met the inclusion criteria, were included in the study. However arthroscopy reports of only 32 patients were available. The age of the patients ranged from 12 to 71 years with most of the patients between 20 to 40 years (52; 64.2%) of age and mean age of 34.7±12.6 years. Male sex predominated with almost 2/3rd of all cases being male (54; 66.7%).



**Figure 2. Sensitivity, specificity and accuracy of MRI**

Non sports injury predominated over sports injuries in our study (52; 64.2% Vs 26; 32.1%). Road traffic accidents were much less common indication for MRI knee accounting for only 3 cases in our study. Twisting and combined mechanism of injury was the two most common mechanisms of internal knee injuries.

**Table 1. MRI findings in knee joint injury.**

Findings	Number (%) n=81
----------	-----------------

<b>ACL</b>	
Tear	34(42.0%)
Partial tear	6(7.4%)
Normal	41(50.6%)
<b>PCL</b>	
Tear	3(3.7%)
Partial tear	4(4.9%)
Normal	74(91.4%)
<b>Medial Meniscus</b>	
Tear	33(40.7%)
Intra substance degeneration (Grade I and II)	29(35.8%)
Normal	19(23.5%)
<b>Lateral Meniscus</b>	
Tear	9(11.1%)
Intra substance degeneration (Grade I and II)	18(22.2%)
Normal	55(66.7%)
<b>Others</b>	
Bony contusion	31 (38.3%)
Medial collateral ligament tear	8(9.8%)
Lateral collateral ligament tear	2(2.4%)
<b>Joint effusion</b>	<b>71(87.7%)</b>

Anterior cruciate ligament tear was the most common internal ligament tear accounting for 34(42%) of cases followed by medial meniscus tear in 33(40.7%). Bony contusion was common and was seen in 31(38.3%) of knees. (Table 1) Medial meniscal tear and ACL tear in combination was seen 17(20.98%) of cases. Twisting (14; 42.4%)was the most common mechanism involved in medial meniscus tear while combined mechanism of injury was most common mechanism for ACL tear (16; 47.05%).

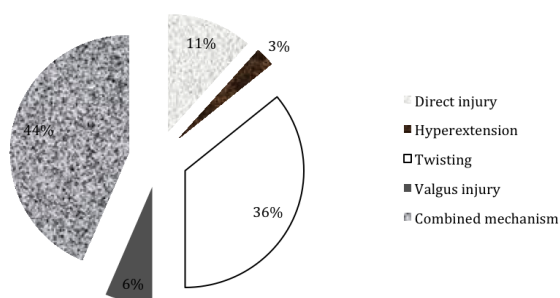
A total of 32 arthroscopy reports were available on follow up of the patients. ACL tear was seen in 84.3% of cases, PCL tear was not encountered in arthroscopy. Medial and lateral meniscal tear was seen in 59.3% and 28.2% of cases respectively. (Table 2)

**Table 2. Arthroscopy Findings.**

Characteristics	Number (%) n=32
ACL tear	27(84.37)
PCL tear	0(0)
Medial meniscus tear	19(59.37%)

**Lateral meniscus tear** 9(28.2%)

Most patients diagnosed as ACL by tear MRI were found to have ACL tear on arthroscopy (26 out of 27). There was one false negative, which was seen in a patient with complex tear of both lateral and medial meniscus. One false positive case was noted which was diagnosed as partial tear on MRI and was normal on Arthroscopy. All cases diagnosed as medial meniscus tear on MRI were seen to have medial meniscus tear on arthroscopy. There was one false negative case, which was diagnosed as intra substance degeneration of medial meniscus on MRI but was found to have tear on arthroscopy. Lateral meniscus tear was also diagnosed fairly well with MRI with one false positive and 3 false negative case, which was all associated with ACL tear. The sensitivity of MRI for diagnosis of ACL tear and medial meniscus tear was 96.3% and 94.7% respectively. Specificity for ACL tear was however only 80% and that for medial meniscus tear was 100%. (Figure 2)



**Figure 1. Mechanism of knee injuries.**

**DISCUSSION**

The knee is the most commonly injured joint in the adolescent athlete. The age group commonly involved in knee injury was between 20 to 40 years in our study, which is the adult population with high amount of physical activity and are the age group with highest injury.<sup>4</sup> This population is also the working population and knee injury might result in absence from work reducing productivity; which is one cause to give more attention to knee injuries.

ACL tear was the commonest internal derangement noted in our study, a result similar to other studies.<sup>5-7</sup> However the proportion of partial tear to complete tear was quite low in our study accounting for only 15% of cases while other studies in the region showed a higher proportion of partial tear accounting more than 50% of total ACL tear.<sup>5,7</sup> Medial meniscus tear was the second most common

internal derangement after ACL injury. The proportion of medial meniscus tear was shown to be 50% to 58% in study evaluating MRI in knee joint injuries.<sup>5,6</sup> Also the other studies in South Asia showed medial meniscus tear to be second only to ACL tear more common than lateral meniscus tear.<sup>7,8</sup> Lateral meniscus tear was seen in 11% in our study much less common than medial meniscus tear which has also been seen in several other studies.<sup>5-9</sup> The involvement of medial meniscus more commonly is due to the fixity of medial meniscus which makes it more prone to injury than lateral meniscus.<sup>10-12</sup> ACL, PCL and medial meniscus tear was associated in most cases. Discoid lateral meniscus was seen in two cases, which is a predisposing condition for lateral meniscus injury.

The most common mechanism of ACL tear is deceleration with change in direction a mechanism with combined movements, which was classified as combined mechanism in our study, was the most common mechanism for ACL tear. The classical mechanism of injury involving the meniscus tear is acute rotational force on weight bearing limb commonly described as twisting which was seen as most common mechanism responsible for medial meniscus tear in our study.<sup>11</sup>

There was high correlation between MRI and arthroscopy with sensitivity for ACL and medial meniscus tear more than 90% and accuracy above 90% for both. However the sensitivity of MRI for lateral meniscus tear was lower than shown by previous systemic review.<sup>3</sup> The negative correlation of MRI and arthroscopy of lateral meniscus tear was associated with ACL tear, which is known to cause reduced sensitivity for ACL tear.<sup>3</sup> One patient with partial PCL tear and two patients with complete PCL tear diagnosed on MRI underwent arthroscopy but arthroscopy could not detect PCL tear. There was limitation to the arthroscopic assessment of PCL due to unavailability of 700 scope which tends to miss PCL tear and injury to posteromedial aspect of joint surface, which might be the cause for the finding.

We had certain limitations to our study. The study was timed bound hospital based study with a small sample size. The sample population was only patients with knee injury who underwent MRI, which may not represent true demographics of knee injury. Also not all patients with MRI knee underwent arthroscopy in our center, thus reducing the effective sample size of our study for evaluating diagnostic value of MRI. Arthroscopy in our hospital was performed only with a 300 scope, which could miss the PCL injury in arthroscopy. We did not include clinical assessment in our study. The mechanism of injury was as briefed by the patients and could be a source of memory bias.

## CONCLUSIONS

The diagnostic value of MRI for diagnosing internal derangement of knee was high even with a low Tesla (0.3 T) MRI thus emphasizing the role of MRI as a non-invasive alternative to diagnostic arthroscopy. MRI of knee is thus a useful diagnostic modality in evaluating injuries of the knee especially the tear of ACL and meniscus and should be performed in all patients prior to therapeutic arthroscopy replacing diagnostic arthroscopy.

## REFERENCES

1. Majewski M, Susanne H, Klaus S. Epidemiology of athletic knee injuries: A 10-year study. *The Knee*. 2006;13(3):184-8. doi: <http://dx.doi.org/10.1016/j.knee.2006.01.005>.
2. Hetta W, Niazi G. MRI in assessment of sports related knee injuries. *The Egyptian Journal of Radiology and Nuclear Medicine*. 2014;45(4):1153-61. doi: <http://dx.doi.org/10.1016/j.ejrn.2014.06.009>.
3. Oei EH, Nikken JJ, Verstijnen AC, Ginai AZ, Hunink MM. MR Imaging of the Menisci and Cruciate Ligaments: A Systematic Review. *Radiology*. 2003;226(3):837-48.
4. Gage BE, McIlvain NM, Collins CL, Fields SK, Comstock RD. Epidemiology of 6.6 million knee injuries presenting to United States emergency departments from 1999 through 2008. *Academic emergency medicine : official journal of the Society for Academic Emergency Medicine*. 2012;19(4):378-85. Epub 2012/04/18. doi: [10.1111/j.1553-2712.2012.01315.x](https://doi.org/10.1111/j.1553-2712.2012.01315.x). PubMed PMID: 22506941.
5. Gupta M, Rauniyar R, Karn N, Sah P, Dhungel K, Ahmad K. MRI Evaluation of Knee Injury with Arthroscopic Correlation. *Journal of Nepal Health Research Council*. 2014; 12(26):63-7.
6. Sharma U, Shrestha B, Rijal S, Bijukachhe B, Barakoti R, Banskota B, et al. Clinical, MRI and Arthroscopic Correlation in Internal Derangement of Knee. *Kathmandu University Medical Journal*. 2012;9(3):174-8.
7. Singh JP, Garg L, Shrimali R, Setia V, Gupta V. MR Imaging of knee with arthroscopic correlation in twisting injuries. *Indian Journal of Radiology and Imaging*. 2004;14(1):33.
8. Gupta K, Guleria M, Sandhu P, Galhotra R, Goyal A. Clinico-radiological correlation in the diagnosis of ligament and meniscus injuries at knee joint: A prospective study. *Saudi Journal of Sports Medicine*. 2013;13(1):22.
9. Liu X S, Xu J R, Hua J, Wang B S. MRI diagnosis in meniscal tears: a meta analysis. *Chinese Journal of Radiology* 2007; 41(7): 731-736.
10. Haaga JR, Dogra VS, Forsting M, Gilkeson RC, Ha HK, Sundaram M, editors. *CT and MRI imaging of whole body*. 5th ed. Ohio: Mosby; 2009.
11. Drosos GI, Pozo JL. The causes and mechanisms of meniscal injuries in the sporting and non-sporting environment in an unselected population. *The Knee*. 11(2):143-9. doi: [10.1016/S0968-0160\(03\)00105-4](https://doi.org/10.1016/S0968-0160(03)00105-4).
12. Berquist TH. *MRI of the Musculoskeletal System*: Lippincott Williams & Wilkins; 2012.