

# Cysticercosis of the Tongue

Sharma BP,<sup>1</sup> Gaunt F,<sup>1</sup> Sigdel B<sup>2</sup>

<sup>1</sup>Dental Department, Patan Hospital, Patan Academy of Health Sciences, Lagankhel, Lalitpur, Nepal, <sup>2</sup>Department of Pathology, Patan Hospital, Patan Academy of Health Sciences, Lagankhel, Lalitpur, Nepal.

## ABSTRACT

Cysticercosis is a condition in which a human being acts as the intermediate host of *Taenia solium*, a pork tape worm. The oral mucosa is an uncommonly involved site. A rurally living 35 year old vegetarian female presented with a swelling over the right side of her tongue of seven months duration. Histopathology of excisional biopsy revealed it to be cysticercosis. Diagnosis of cysticercosis was clinically unsuspected. The patient was referred to the general medical clinic for further treatment.

**Keywords:** cysticercosis; oral; rare disease; *Taenia solium*.

## INTRODUCTION

Cysticercosis is a condition characterized by the occurrence of lumps containing the larvae of *Taenia Solium*. It occurs following ingestion of eggs of *Taenia Solium* through contaminated water or food. The cysts are seen in different regions of the body including striated muscle, subcutaneous tissues, the nervous system and the eye.<sup>1</sup>

The *Taenia solium* is found in the small intestine of men; who act as the definitive host. The pig is the intermediate host. When undercooked and contaminated pork is eaten, the larvae reach the intestine where they develop into adult tapeworms.<sup>2</sup> Man can also act as intermediate host.<sup>3</sup>

## CASE REPORT

A 35 year old vegetarian female from the Kabhre district of Nepal presented to the dental department of Patan Hospital with a history of a swelling over the right side of her tongue. This had been noticeable for seven months. She also complained of migrating 'lumps' in different parts of body having occurred intermittently for one year.

Previously she had attended a local pharmacy and had taken some medication, suspected to be antibiotic; although this is not recorded or known. The lesion on the tongue gradually progressed and she had difficulty in speech and eating due to the size.

No history of visual disturbances, seizures or headaches were reported. She did not use cigarettes or tobacco. She had a history of regular high consumption of home brew alcohol of unknown strength. On initial inspection no obvious swellings were noted. The cervical and the submandibular lymph nodes were not palpably enlarged.

Oral examination revealed a well defined, non tender, firm nodular lesion with smooth surface approximate 1.5 cm in diameter on the right dorsal tongue. The overlying mucosa was intact. The routine haematological and urine test was normal. The lesion was provisionally diagnosed as a benign fibroma.

Excision biopsy of the lesion was performed under local anaesthesia and subjected to histopathological examination. The microscopic results showed a thick fibrous capsule surrounded by inflammatory cells. Inside the cyst, typical invaginated segments representing the globular scolex with suckers (head of *Taenia solium*) were seen (Figure 1).

**Correspondence:** Dr. Bishnu Prasad Sharma, Dental Department, Patan Hospital, Patan Academy of Health Sciences, Lagankhel, Lalitpur, Nepal. Email: bishnunl@yahoo.com, Phone: 9841336289.

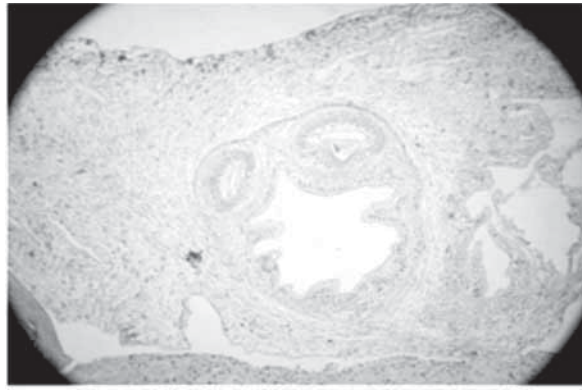


Figure 1. Exisional biopsy view at magnification x10. Stained with Eosin and Haematoxylin.

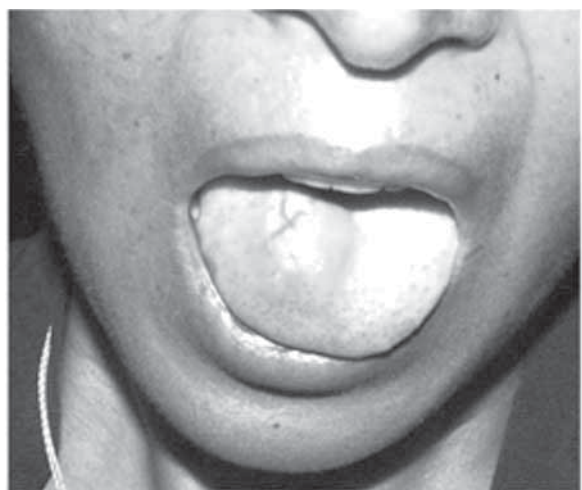


Figure 2. Post operative early healing.

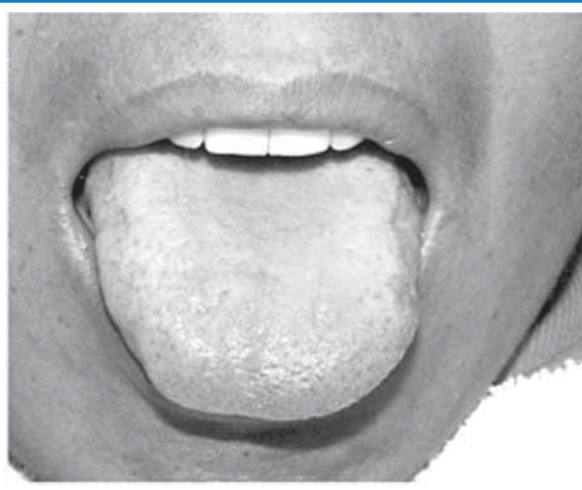


Figure 3. Post operative view.

The final diagnosis was that of Cysticercosis of tongue mucosa. Later stool examination was also carried out

and was negative for eggs. C.T. could not be performed due to unavailability at the time in Nepal.

The patient was sent to the medical referral clinic for further treatment. At this time she was treated with albendazole. She reattended following treatment showing good overall healing with no functional morbidity (Figure 3).

### DISCUSSION

Amatya et al report 62 cases of Cysticercosis, among which 6 cases had lesions in the oral mucosa.<sup>4</sup> The tongue is most commonly involved.<sup>5</sup> Cysticercosis can involve almost every system of the body. Serious complications occur with ocular and cerebral involvement.<sup>6</sup> The cysticerci are spherical, milky white cysts containing fluid and single invaginated scolex. The adult worm measures 2.5 to 3 meters and consists of a scolex with several hooks and a body comprising about 1,000 proglottids.<sup>7</sup> Each proglottid contains 50,000-60,000 fertile eggs, which remain viable for long time in water, soil and vegetation.<sup>8</sup>

These eggs may infect pigs and cycle goes on or alternately human being gets infected by parasite in three ways:

1. Ingestion of food or water contaminated by infected human faeces containing *T. solium* eggs;
2. Oral transmission of eggs via the hands or carriers of adult worm;
3. Internal autoinfection by regurgitation of eggs into the stomach after reverse peristalsis.<sup>8</sup>

The clinical effects of cysticercosis vary depending on site of larval lodging, larval burden, and host reaction. The effects include seizures, headaches, focal neurologic presentation, visual disturbances, localised skeletal muscle nodules and pain.<sup>9</sup>

The continuous action of the tongue and buccal muscles may prevent the larvae from developing into adult cysticercus cysts.<sup>6</sup> The differential diagnosis of oral cysticercosis depends on the location of the lesion. Nodules on the lips and cheeks may be considered as fibroma, lipoma, mucocele, pyogenic granuloma or pleomorphic adenoma. Nodules on the tongue may be considered as fibroma, pyogenic granuloma, granular cell myoblastoma or rhabdomyoma.<sup>3</sup>

Fine needle aspiration is a cost-effective, quick and reliable method of diagnosis. Larval fragments are noticed in FNA smears. The larva is identifiable by its lightly stained outer wavy membrane and multiple tiny

ovoid nuclei in the fibrillary stroma beneath, along with inflammatory cells.<sup>9</sup> This could probably be the simplest of all and would exclude the other conditions such as lipoma or mucocele.<sup>9</sup> Radiologic imaging, serology and tissue biopsy can be used to confirm a diagnosis of cysticercosis. Magnetic resonance imaging also is a useful tool for diagnosing neurocysticercosis and may be better than CT at detecting spinal, brainstem, or intraventricular lesions.<sup>10</sup>

Treatment of cysticercosis is symptom driven. Deciding treatment options is difficult because of the number of caveats that must be considered. Thus evidence-based recommendations are difficult.<sup>10</sup> Albendazole or Praziquantel are effective in the treatment of disseminated cysticercosis, usually with adjunctive steroid therapy.<sup>10</sup> At times, treatment for oral cysticercosis is surgical enucleation; especially in undiagnosed cases.

## CONCLUSIONS

This case report could add to the series of Oral cysticercosis in the form of lingual involvement, diagnosed by excisional biopsy and histopathological examination.

The cysticercosis should also be considered in the differential diagnosis of nodular swelling in the oral cavity.

To prevent cysticercosis, such as efficient hand washing and safe food preparation should be implemented universally.

## REFERENCES

1. Knight R, Gut cestodes. In: D.J. Weatherall, eds. Oxford text book of medicine: UK Edition, 3<sup>rd</sup>vol, 1990:959-64.
2. Timosca G, Gavrilita L. Cysticercosis of the maxillofacial region: A clinicopathologic study of five cases. *Oral Surg, Oral Med, Oral Pathol.* 1974;37(3):390-400.
3. Lustman J, Copelyn M. Oral cysticercosis: Review of the literature and report of two cases. *Int J Oral Surg.* 1981;10(5):371-75.
4. Amatya BM, Kimula Y. Cysticercosis in Nepal: a histopathologic study of sixty-two cases. *Am J Surg Pathol.* 1999 Oct;10:1276-9.
5. Bedi TR, Pandhi RK, Bhutani LK. A case of cysticercosis cellulosa involving the oral cavity. *Int J Dermatol.* 1974 Jul-Aug;13(4):188-9.
6. Indira C, Ramesh V, Misra RS. Association of oral cysticercosis and post kalaazar dermal leishmaniasis. *Int J Oral Maxillofac Surg.* 1990 Oct;19(5):266-67.
7. Reddi SP, Morales MJ, Addante RR. Solitary lesion in the Masseter Muscle. *J Oral Maxillofac Surg.* 2001 Jan;59(1):71-75.
8. Wanjari SP, Patidar KA, Parwani RN, Tekade SA. Oral cysticercosis: a clinical dilemma. *BMJ Case Reports.* 2013; doi: 10.1136/bcr-2012-007482.
9. Mazhari NJ, Kumar N, Jain S. Cysticercosis of the oral mucosa: aspiration cytologic diagnosis. *J Oral Pathol Med.* 2001 March;30(3):187-9.
10. Kraft R. Cysticercosis: An Emerging Parasitic Disease. *J Am Fam Physician.* 2007 Jul;76(1):91-6.