

Interstitial Lung Disease as Initial Manifestation of Systemic Lupus Erythematosus

Kumar A,¹ Khan U,¹ Shrestha B,² Thapa S,³ Rizvi N¹

¹Jinnah Postgraduate Medical Center, Karachi Pakistan, ²Bolan Medical College, Quetta, Pakistan, ³Vayodha Hospitals Pvt. Ltd., Kathmandu, Nepal.

ABSTRACT

Interstitial lung disease (ILD) is a group of disease characterized by fibrosis and scarring of the lung while Systemic Lupus Erythematosus is a multisystem disorder and both of these diseases are of unknown etiologies. Interstitial lung disease, as a presenting feature of SLE without any significant systemic involvement is a unique presentation and this case reports such example.

Keywords: interstitial lung disease; systemic lupus erythematosus.

INTRODUCTION

Severe parenchymal lung disease though is uncommon, pulmonary complications of SLE are protean and include acute and chronic lupus pneumonitis, Interstitial lung disease (ILD) or chronic interstitial pneumonitis (CIP), cavitary pulmonary nodules, pulmonary hypertension, pulmonary vasculitis, pulmonary embolism, bronchiolitis obliterans with or without organizing pneumonia (BOOP), diaphragmatic dysfunction and shrinking lung syndrome, alveolar hemorrhages and opportunistic pulmonary infections (tuberculosis, fungal, bacterial or uncommon viral) or immunosuppressive drug toxicity.¹⁻⁹ Pulmonary involvement is very common in systemic lupus erythematosus (SLE). It is usually seen in cases of long standing SLE, however in only 2-3% it is the initial manifestation.^{5,7} Pulmonary involvement in the form of Interstitial Lung Disease (ILD) has been seen in 3-13% (3-8% in some series and up to 9% in one series) cases of SLE.^{6,9-11} Pleurisy, coughing and/or progressive dyspnea are the usual complains.⁹ Differential diagnosis requires exclusion of other diseases such as extrinsic allergic alveolitis, sarcoidosis, tuberculosis, atypical pneumonia. HRCT is sensitive in detecting pulmonary changes in SLE, but can be negative in few cases.^{8,12} Immunologic abnormalities and lung function tests are important tools for diagnosis, and were the major diagnostic clues along with history and radiologic evidence of interstitial lung disease and oral ulcers in our case. The uniqueness of our case is that, not only

ILD was the initial manifestation of SLE but there was a dearth of systemic involvement and that there was also a possibility of accompanying COPD; suggested by long term biomass exposure and hyper inflated lung fields (Lungs in SLE are usually small, either due to damage by ongoing fibrosis or due to diaphragmatic paralysis; a direct consequence of SLE).^{10,11}

CASE

A 40 year old Asian woman was admitted to the Pulmonology unit of Jinnah Postgraduate Medical Center, Karachi, after being referred to its outpatient department with complains of progressive dyspnoea for 1 year. She also described having recurrent episodes of painless oral ulcers from past 2 years. She reported having parrots at home for past 25 years and that she uses woods for cooking at home. She never smoked or took alcohol. There was no history of cough, chest pain, fever, chills, arthralgia, photosensitivity, rash, night sweats or weight loss. Past medical and surgical history was unremarkable. She is married and had four normal pregnancies without any abortions. She had a regular menstrual cycle. She is a housewife; did not give any history of recent travel, she did not have any history of tuberculosis and denied any contact with active tuberculosis patient. On examination, she was anemic and clubbed. Chest revealed bilateral fine crackles. Rest of the examination was unremarkable. She was

Correspondence: Dr. Ashok Kumar, Jinnah Postgraduate Medical Center, Karachi, Pakistan. Email: ashoka_pj@yahoo.com, Phone: +923222619128.

afebrile, but had tachycardia (heart rate of 100bpm) and respiratory rate of 14 breaths/minute.

On auscultation, loud crackles were audible over both lungs. Chest X-ray revealed hyperinflated lung fields with bilateral reticulonodular shadowing and hilar congestion. Arterial Blood Gas analysis revealed chronic hypercapneic respiratory failure (pH 7.41, PO₂ 45.6, PCO₂ 51.8, HCO₃ 27.4mmol/l, SPO₂ 85.5%). Her Haemoglobin was 7.4mg/dl, MCV was 70, and WBC count was 6.6x10³/µl with a differential showing 70% neutrophils, 25.5% lymphocytes and 2% eosinophils. She had C reactive protein (CRP) value of 5mg/dl. Urine analysis and serum biochemistry profile did not reveal any abnormality. High Resolution Computed Tomography (HRCT) was suggestive of an interstitial pattern of lung involvement.

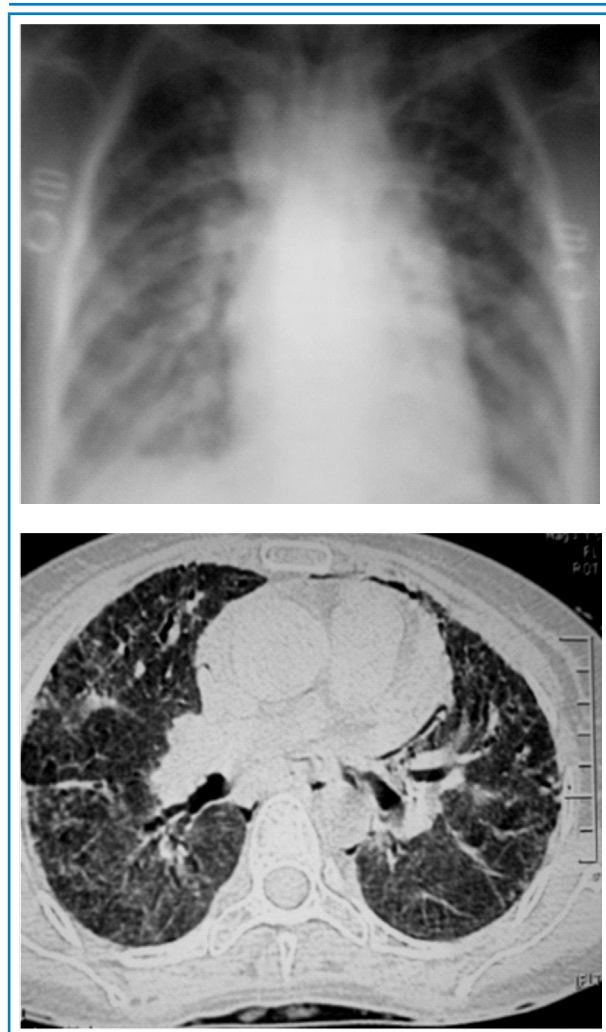


Figure 1. X rays film and CT scan film of patient.

Immunologic testing was positive for antinuclear antibodies (ANA homogenous positive), including those to double stranded DNA suggesting diagnosis of SLE, low complement levels with C3 70 mg/dl and C4 09 mg/dl

further strengthen the possibility of SLE. Angiotensin Converting Enzyme (ACE) levels and eye examination was found to be normal and she had a negative Montoux test. Spirometry and lung volumes could not be determined due to poor effort. On a six-minute walk test, Patient started with 90% O₂ saturation and pulse 82 bpm per minute. She could walk only 380 meters with drop in her O₂ saturation to 76% and pulse 110 bpm, a pattern suggesting exertional hypoxia. Echocardiography was done; that demonstrated normal size left ventricle with normal systolic function, no left ventricular diastolic dysfunction, estimated pulmonary artery pressure Of 45 mmHg that is pulmonary artery hypertension (PAH), ejection fraction (EF) was 55%.

DISCUSSION

Systemic lupus erythematosus is a chronic autoimmune disorder. It is a clinical syndrome with a complex multifactorial etiology characterized by micro vascular inflammation and generation of antibodies that can affect almost any organ system. The course of SLE is highly variable and it has a broad range of clinical manifestations.

The most common initial manifestation of SLE is arthralgia or arthritis,¹³ with a frequency of 48% in patients followed for 10 years.¹⁴ Pulmonary involvement is common but only in 2-3% of cases; it is the initial manifestation of lupus.^{5,7} Respiratory disease in lupus may be due to direct involvement or a consequence of disease affecting other organ system. Pleura are most commonly involved and manifestations have been reported in 30-60% of SLE patients, at some point in the course of the disease.^{6,9}

Pleurisy, coughing and/or dyspnea are often the first clues to either lung involvement or SLE itself.⁹ Decreased diffusing capacity of carbon monoxide (DLCO) along with abnormal chest x-rays may be detected in asymptomatic patients.⁹ Pulmonary abnormalities do not correlate with immune parameters.⁹

Systemic Lupus Erythematosus and Interstitial Lung Disease:

Clinically significant ILD complicates SLE in 3-13% (3-8% in some series and up to 9% in one series) patients, but is rarely severe.^{6,9-11} The onset is usually insidious but it may be preceded by episode of acute pneumonitis.^{6,10,11} The presence of Anti-Ro (Anti SS-A) antibodies may be a risk factor for SLE-associated chronic ILD,^{6,15} asymptomatic involvement is more common and pulmonary function test (PFT) shows restrictive pattern with decreased lung volume.^{6,9} Patients present with chronic non-productive cough, dyspnea, recurrent pleuritic chest pain and decreased exercise tolerance.⁹ The clinical

and pathological findings are similar to those in other rheumatic diseases with ILD and in idiopathic pulmonary fibrosis (IPF). The presence of lupus is suggested by the characteristic extra pulmonary and serological manifestations. Besides Pulmonary Function Test (PFT) abnormalities, there is decreased DLCO and oxygen desaturation with exercise.⁹ Imaging studies may reveal bibasilar or diffuse infiltrates, pleural disease, honeycombing, and decreased lung volumes with diaphragmatic elevation.^{1,6,9} HRCT may be extremely helpful in diagnosis and two patterns are frequently seen; ground glass appearance (consistent with biopsy showing cellular infiltrate, pattern of non specific pneumonia, NSIP) or reticular appearance (consistent with biopsy showing fibrotic pattern, one seen in usual interstitial pneumonia; UIP).^{1,6,9} This differentiation will help determine treatment.¹ Bronchoalveolar lavage (BAL) can also be useful, especially to exclude infection, malignancy and granulomatous disease.⁹ Lung biopsy may only be required if the diagnosis is still in doubt despite the less invasive testing mentioned in the preceding lines; besides UIP and NSIP, other patterns seen include lymphocytic interstitial pneumonitis (LIP), cryptogenic organizing pneumonia (COP) and amyloidosis.^{6,9} Immunostaining shows deposition of immunoglobulin and complement in the alveolar septae.¹¹ Treatment involves use of corticosteroids either alone or in combination with an additional immunomodulator. Patients with well established pulmonary fibrosis are unlikely to benefit from an immunosuppressive therapy and this should be determined near the time of diagnosis.⁹ In case of progressive or severe disease, high dose steroid therapy is initiated along with intravenous/oral cyclophosphamide with gradual transition to azathioprine or mycophenolate whereas in less severe cases or those less tolerant to cyclophosphamide, the latter two agents may be introduced early in treatment.^{9,16} Investigations are underway on agents such as pirfenidone and those targeting tyrosine kinase inhibitions, for the treatment of fibrotic lung disease.⁹

CONCLUSIONS

Pleuropulmonary disease may occur in a well-established case of lupus or may be the first manifestation of SLE (2-3%). ILD is found in 3-13% cases, and mostly in cases of well established SLE. Our case was unique because the patient presented with ILD without any significant systemic involvement and with probable COPD (biomass exposure and hyper inflated lung fields), and to the best of authors' knowledge, first such case to be reported. Since many of the abnormalities present with non specific findings, high index of suspicion and extensive workup is required. HRCT and immunologic parameters are most useful tools in their early diagnosis.

REFERENCES

- Cheema GS, Quismoro FP. Interstitial Lung Disease in Systemic Lupus Erythematosus: *Curr OP Pulm Med*. 2000; 424-9.
- Bresford MW, Cleary AG, Sills JA, Couriel J, Davidson JE. Cardiopulmonary Involvement in Juvenile Systemic Lupus Erythematosus. *Lupus*. 2005;14:152-8.
- Ciftçi E, Yağmıkaya F, Ince E, Ekim M, Ileri M, Orgerin Z, Fitöz S, Güriz H, Ayser AD, Dogru U. Pulmonary involvement in childhood-onset systemic lupus erythematosus: a report of five cases. *Rheumatology*. 2004;43:587-91.
- Downey C, Leiberman G. Systemic lupus erythematosus: Pleuropulmonary manifestations. [online]. 2010. Available from: URL: <http://www.eradiology.bidmc.harvard.edu/>
- Dubois EL TDL. Clinical manifestations of systemic lupus erythematosus: Computer analysis of 520 cases. *JAMA*. 1964;190(2):104-111.
- Keane MP, Lynch JP, 3rd. Pleuropulmonary manifestations of systemic lupus erythematosus. *Thorax*. 2000 Feb;55(2):159-66.
- West JB. Pulmonary pathophysiology. Baltimore: Lippincott Williams & Wilkins; 2008.
- Kakati S, Doley B, Pal S, Deka UJ. Pulmonary manifestations in systemic lupus erythematosus (SLE) with special reference to HR CT. *J Assoc Physicians India*. 2007 Dec;55:839-4.
- Peter HS, Paul FD. Pulmonary manifestations of systemic lupus erythematosus in adults. [online]. 2010. Available from: URL:<http://www.UpToDate.com>. V19.3.
- Eisenberg H, Dubois EL, Sherwin RP, Balchum OJ. Diffuse interstitial lung disease in systemic lupus erythematosus. *Ann Intern Med*. 1973;79(1):37-45.
- Weinrib L, Sharma OP, Quismorio FP Jr. A long-term study of interstitial lung disease in systemic lupus erythematosus. *Semin Arthritis Rheum*. 1990 Aug;20(1):48-56.
- Koller HK, Burghuber OC, Kiss D. Pulmonary Manifestation of Systemic Lupus Erythematosus (SLE) with normal High Resolution Computer Tomography: a case report. *Chest*. 2004 Oct;126:(4)971-72.
- Cronin ME. Musculoskeletal manifestations of systemic lupus erythematosus. *Rheum Dis Clin North Am*. 1988;14:(1):99-116.
- Cervera R, Khamashta MA, Font J, Sebastiani GD, Gil A, Lavilla P, et al. Morbidity and mortality in systemic lupus erythematosus during a 10-year period: a comparison of early and late manifestations in a cohort of 1,000 patients. *Medicine (Baltimore)*. 2003 Sep;82(5):299-308.
- Hedgpeth MT, Boulware DW. Interstitial pneumonitis in antinuclear antibody-negative systemic lupus erythematosus: a new clinical manifestation and possible association with anti-Ro (SS-A) antibodies. *Arthritis Rheum*. 1988 Apr;31(4):545-8.
- Swigris JJ, Olson AL, Fischer A, et al. Mycophenolate mofetil is safe, well tolerated, and preserves lung function in patients with connective tissue disease-related interstitial lung disease. *Chest*. 2006;130:30-6.