

## Mucopolysaccharidosis Type II with Inguinal Hernia

Rayamajhi A,<sup>1</sup> Pokharel PJ,<sup>1</sup> Chapagain R,<sup>1</sup> Rayamajhi AK<sup>2</sup>

<sup>1</sup>National Academy of Medical Sciences, Department of Pediatrics, Kanti Children's Hospital, Maharajgunj, Kathmandu,

<sup>2</sup>Department of Obstetrics and Gynaecology, B & B Hospital, Gwarko, Lalitpur, Nepal.

### ABSTRACT

Mucopolysaccharidosis Type II (Hunter syndrome) is a rare X-linked recessive storage disorder caused by deficiency of lysosomal enzyme iduronate-2-sulfatase, causing excess accumulation of glycosaminoglycans in the lysosomes resulting in cellular damage, organ failure and death. Severe subtype develops characteristic clinical features and cognitive impairment early and die in second decade of life. In a resource poor setting, we report a case of Hunter syndrome, severe subtype, based on global development delay, coarse facies, short stature, hepatosplenomegaly and dysostosis multiplex on X-ray with unusual large congenital inguinal hernia. The diagnosis was important because of risk of recurrence of hernia after repair.

**Keywords:** glycosaminoglycans; Hunter syndrome; iduronate-2-sulfatase deficiency; inguinal hernia; mucopolysaccharidosis.

### INTRODUCTION

Mucopolysaccharidosis (MPS) is a group of rare hereditary metabolic disorder which results from complete absence or lack of normal functioning of one of the 11 lysosomal enzymes required to break down glycosaminoglycans (GAGs), such as dermatan sulfate, heparin sulfate, keratin sulfate and chondroitin sulfate necessary for the formation of cornea, skin, bone, cartilage and connective tissues. It was first described by Charles Hunter in 1917.<sup>1</sup> The prevalence MPS ranges from 3.4 to 4.5 per 100000 births.<sup>2</sup> They are mainly of seven types I, II, III, IV(A), IV(B), VI, VII and IX. MPS type II (MPS II) or Hunter syndrome is one of the rarest with estimated prevalence of 1 in 170,000 male live births.<sup>3</sup> Although indirect inguinal hernias have been suspected in 36% in both types I and II earlier,<sup>4</sup> associated congenital inguinal hernia has not been commonly described. Our patient of MPS II presented with a large congenital bilateral inguinal hernia. Like most developing countries, urinary GAG level and enzyme assay for serum iduronate-2-sulfatase (I2S) level estimate was not available for confirmation of diagnosis.

### CASE REPORT

A 2-year-old boy presented with swelling in the groin since birth with a history of fever and cough for four days. There was decreased weight gain and global developmental delay but no history of constipation, lethargy, jaundice, diarrhea, seizure or loss of consciousness. Mother was not on any medication during prenatal and perinatal period. Anthropometry revealed significantly malnourished [weight 8 Kg (weight-for-age <-3SD), height 77 cm (height-for-age <-3SD)] and the upper segment: lower segment ratio was reduced at 1.5. There was microcephaly [head circumference 42.5 cm (<-3SD)] with frontal bossing, prominent supraorbital ridge, depressed nasal bridge, button short upturned and broad nose, flared nostril, short neck and coarse facial features (Figure 1a). He also had small stubby fingers. He could not stand with support and spoke only a few monosyllabic words. On ocular examination, his fundus appeared normal. Abdomen was distended with a protruding umbilicus. He had hepatomegaly of 5 cm below right coastal margin in mid-clavicular line (liver span 12 cm), firm, smooth surfaced with sharp margin.

**Correspondence:** Dr Ajit Rayamajhi, National Academy of Medical Sciences, Department of Pediatrics, Kanti Children's Hospital, Kathmandu, Nepal. Email: ajitrnp@yahoo.com, Phone: 977-1-4021859.

He also had splenomegaly of 5 cm below left costal margin in mid-clavicular line (Figure 1b). Antero-posterior and lateral X-rays of the dorsolumbar spine showed anterior beaking of lumbar vertebrae (Figure 2a). Vertebral bodies appeared osteoporotic and ovoid due to convexity of the superior and inferior surfaces. The spine was concave in lumbar region anteriorly and vertebral body height appeared normal. X-rays of both hands showed widening with proximal tapering of the metacarpals, bullet shaped phalanges and absent carpal bones (Figure 2b). Lateral X-ray of chest showed wide ribs with tapered posterior ends (paddle and/or spatulated appearance) with clear lung fields (Figure 3). Echocardiography and thyroid function were normal. Although detection of excess GAG (dermatan and heparan sulphates) level in the urine and deficiency of serum I2S level would have been diagnostic for MPS II, both were not available on site. The huge inguino-scrotal swelling was confirmed as inguinal hernia by a pediatric surgeon and ultrasonography. The child received antibiotics for respiratory tract infection, nutritional supplement and planned for herniorrhaphy.

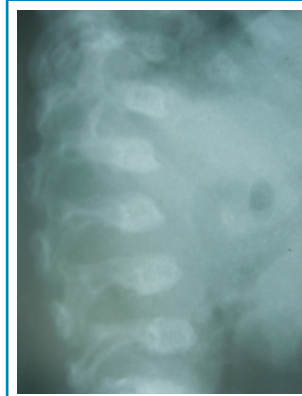


Figure 2a

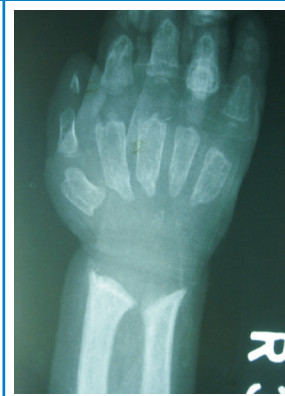

Figure 2b

Figure 2a, 2b. (2a) Lateral X-Rays of dorsolumbar spine showing osteoporotic and ovoid vertebral bodies, anterior concavity of lumbar spine and anterior beaking of lumbar vertebrae. (2b) X-Ray of left hand showing proximal tapering of the metacarpals, bullet shaped phalanges and absent carpals.

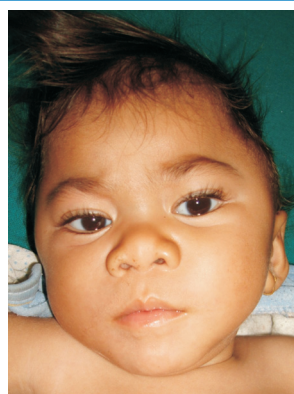

Figure 1a

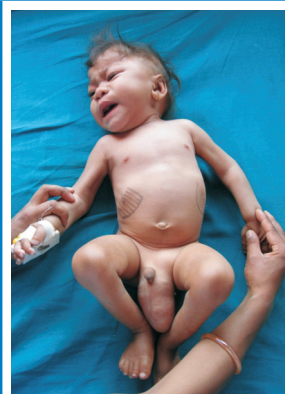

Figure 1b

Figure 1a, 1b. (1a) Facial dysmorphism demonstrating characteristic coarse facies, microcephaly, frontal bossing, depressed nasal bridge, broad nose, flared nostril and short neck. (1b) Other signs of Mucopolysaccharidosis such as distended abdomen, hepatosplenomegaly and protruding umbilicus and unusually large bilateral inguinal hernia.

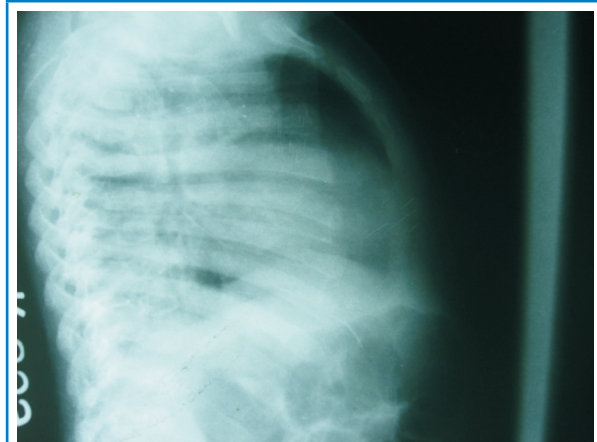


Figure 3. Chest X-Ray lateral view of the same patient showing clearly wide ribs with tapered posterior end giving it a spatulated appearance.

## DISCUSSION

MPS is a group of inherited diseases characterized by defective lysosomal enzymes responsible for the degradation of mucopolysaccharides, which are major components of intercellular connective tissue. In affected individuals, undegraded or partially degraded GAG accumulates within the lysosomes and is excreted in excess in the urine, which is responsible for progressive cellular damage causing different clinical manifestations and death.<sup>5</sup>

MPS II is rare and is caused by a deficiency of serum I2S.<sup>3</sup> It is the only X-linked recessive MPS disorder, all others are autosomal recessive. It is of two subtypes, severe

(type II, HA) and mild (type II, HB) based on the length of survival and presence of neurological involvement.<sup>3,6</sup> Although, patients typically appear normal at birth, characteristic clinical features appear between two and four years in the severe form and during second decade of life in the milder form. Severely affected patients have severe mental retardation, increased Mongolian spots and usually die within second decade of life because of respiratory or cardiac failure. Milder cases have mild mental retardation, normal stature, subtle clinical features and slow disease progression. They usually die in the forties.

The diagnosis of MPS is suspected in a child with characteristic facial features, short stature, macroglossia, hoarse voice, hearing loss, multi-system involvement, hepatosplenomegaly, dysostosis multiplex with excess heparan and dermatan sulphates in the urine either by quantitative analysis or GAG electrophoresis. Confirmation of MPS II require demonstration of absent or low I2S activity in leukocytes, fibroblasts or serum.<sup>5,6</sup> Gene analysis help to identify female carriers. Prenatal diagnosis by molecular testing or I2S enzyme assay can be done on chorionic villi or amniotic fluid cells.<sup>5</sup>

Until recently, in MPS II, the management was palliative. However, enzyme replacement therapy using idursulfase, a recombinant human I2S, has now been introduced.<sup>6</sup> Bone marrow transplantation and umbilical cord blood transplantation prevent disease progression. Gene therapy is proving encouraging in animal experimental models.<sup>2</sup> Antibiotic for infection, physiotherapy, blood transfusion and nutritional support should be considered. Inguinal hernia is repaired by herniorrhaphy. During repair, emphasis should be on strengthening of the posterior inguinal canal and ligation of hernia sac. This is because recurrence of hernia requiring repair surgery twice has been reported in 30%, thrice 8% and more than thrice 3%.<sup>7</sup> Recurrence of hernia is best avoided by carefully applying Bassini and Halsted technique as compared to Andrews repair.<sup>4</sup>

In our patient, the clinical features such as short stature, organomegaly, depressed nasal bridge, short neck, coarse facial features, brachydactyly and radiological

features such as beaking of vertebrae, proximal tapering of metacarpal bones, bullet shaped phalanges and tapered posterior ends of ribs, developmental delay and absence of corneal clouding suggested MPS II. Further, onset at 2 years and presence of neurological features suggested severe subtype. There were unusual features of microcephaly and large bilateral congenital inguinal hernia. In conclusion, we report timely diagnosis of severe type of MPS II with large inguinal hernia in a resource poor setting which influenced the management.

## ACKNOWLEDGEMENT

We acknowledge the good work of all the staff of Kanti Children's Hospital who were involved in the management of the patient.

## REFERENCES:

1. Hunter C. A rare disease in two brothers. *Proc R Soc Med.* 1917;10:104-16.
2. Martin R, Beck M, Eng C, Giugliani R, Harmatz P, Munoz V, et al. Recognition and diagnosis of mucopolysaccharidosis II (Hunter syndrome). *Pediatrics.* 2008 Feb;121(2):e377-86.
3. Shah GS, Mahal T, Sharma S. Atypical clinical presentation of mucopolysaccharidosis type II (Hunter syndrome): a case report. *Journal of Medical Case Reports.* 2010;4:154.
4. Coran AG, Eraklis AJ. Inguinal Hernia in the Hurler-Hunter Syndrome. *Surgery.* 1967 Feb;61:302-4.
5. Burton BK, Giugliani R. Diagnosing Hunter syndrome in pediatric practice: practical considerations and common pitfalls. *Eur J Pediatr.* 2012;171:631-39.
6. Wraith JE, Scarpa M, Beck M, Bodamer OA, De Meirleir L, Guffon N, et al. Mucopolysaccharidosis type II (Hunter syndrome): a clinical review and recommendations for treatment in the era of enzyme replacement therapy. *Eur J Pediatr.* 2008 Mar;167(3):267-77.
7. Mendelsohn NJ, Harmatz P, Bodamer O, Burton BK, Giugliani R, Jones SA, et al. Importance of surgical history in diagnosing mucopolysaccharidosis type II (Hunter syndrome): Data from the Hunter Outcome Survey. *Genetics IN Medicine.* 2010 Dec;10(10):816-22.