

Late Presentations of Congenital Diaphragmatic Hernia

Bhandari BB¹, Basnet RB²

¹Department of Surgery, Shree Birendra Army Hospital, ²Registrar, Department of Surgery, National Academy of Medical Sciences.

ABSTRACT

The occurrence of congenital diaphragmatic hernia in adults is rare and misleading even to experienced clinicians. In contrast to neonatal diaphragmatic hernias, most of the adult patients present with vague gastrointestinal and respiratory symptoms mimicking other diseases. Hence high index of suspicion is required. When a diagnosis is established, it must be promptly treated surgically in order to avoid complications such as strangulation or bowel perforation. We present two cases of diaphragmatic hernia which were being managed as pulmonary pathologies.

Keywords: bochdalek hernia, morgagni hernia

INTRODUCTION

Lazarus Riverius first described a congenital diaphragmatic hernia (CDH) in 1690, which was found incidentally in a 24 old man at postmortem.¹ Congenital diaphragmatic hernia occurs 1 in every 2000-3000 live births and accounts for 8% of all major congenital anomalies. They are divided into eventration of the diaphragm, posterolateral hernia of Bochdalek, Parasternal hernia of Morgagni-Larrey, and peritoneo-pericardial hernia. They usually become symptomatic during the earlier age and rarely progress on to adulthood. Diagnosis usually become apparent once complications set in, which are either gastrointestinal, respiratory or cardiovascular.²

CASE REPORT

A 26 year old male was brought to the emergency department with complains of generalized abdominal pain, abdominal distension, vomiting and obstipation for 2 days. The patient was being treated with antitubercular medications for past 3 months with no improvement. There was no history of trauma. On examination, the patient was febrile, dehydrated and hypotensive. Abdominal examination revealed generalized distension with guarding and rigidity with absent bowel sounds. Examination of the chest showed decreased air entry in the left side of the chest. Other systemic examinations were normal.

X-ray abdomen showed multiple air fluid levels indicating intestinal obstruction and X-ray chest revealed bowel loops in the left hemithorax with the heart pushed towards the right side, mimicking dextrocardia (Figure 1). Ultrasonogram of the abdomen showed dilated bowel loops and minimal free fluid. Hemogram and biochemical examination were within normal limit. Patient was resuscitated and prepared for an emergency laparotomy.

Laparotomy was performed with a vertical upper midline incision. On opening the abdomen, a 6 by 6 cm defect in the left posterolateral portion of the diaphragm with transverse colon, around 25 cm of small bowel and entire omentum and part of stomach inside the thorax with extensive adhesions was discovered. Adhesiolysis was done and entire content was reduced into the peritoneal cavity. The bowel was viable. The defect in the diaphragm was closed with No. 1 polypropylene in two layers. A left sided chest tube drainage was placed. Peritoneal lavage with normal saline was done and peritoneal drain was placed. A Bogota bag laparostomy was done to prevent abdominal compartment syndrome. The abdominal wall was closed a week later.

A 36 year old female presented to hospital with complains of dull aching pain abdomen, more in the right lower

Correspondence: Lt. Col. Dr. Bharat Bahadur Bhandari, Shree Birendra Army Hospital, Kathmandu, Nepal. Email: drbharatbhandari@yahoo.com.

quadrant, increasing in intensity over past 16 years, not associated with anorexia, vomiting or fever. The pain increased on standing straight and on deep inspiration and decreased on stooping. There was no history of acute abdomen, menstrual irregularity or history of trauma. Except for crepitations on left lower side of chest, no abnormalities were discovered on systemic examination. Routine hemogram and biochemistry were within normal limit. On chest x-ray, homogenous opacity in the left lower zone in paracardiac area with sharp lateral border and silhouetting the cardiac border, suggestive of consolidation was seen (Figure 2).

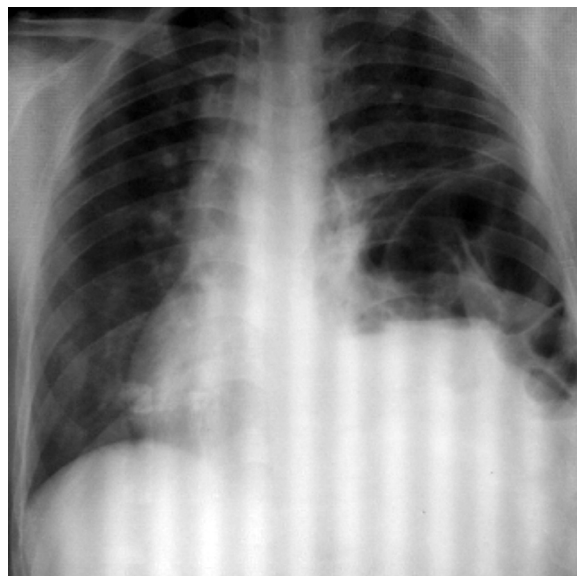


Figure 1. Herniated large bowel loops in the thoracic cavity and heart pushed towards right mimicking dextrocardia.

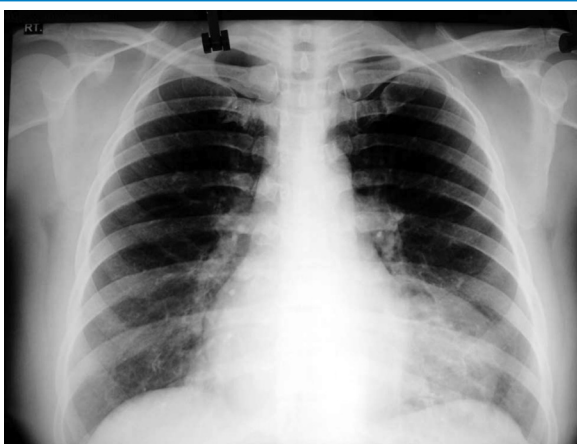


Figure 2. Bowel loops forming homogenous opacity in the left lower zone in paracardiac area with sharp lateral border.

The patient was put on antibiotics and chest x-ray repeated after a week, but no improvement was seen. CT scan of the chest and upper abdomen discovered left Morgagnian hernia with herniated transverse colon. The patient was prepared and elective laparotomy was done through vertical upper midline incision. A defect of about 6 by 6 cm with herniated transverse colon and part of omentum with adhesions was found. Adhesiolysis and reduction of the whole content into the peritoneal cavity was carried out. The defect was closed with No. 1 polypropylene suture, followed by peritoneal lavage and primary closure of the abdomen. The patient made an uneventful recovery and was discharged on the seventh postoperative day.

DISCUSSION

The diaphragm forms from the septum transversum which grows downwards and backwards to meet the dorsal mesentery of the foregut.³ Pleuroperitoneal folds then develop on each side of the septum and extend postero-laterally dividing the chest from abdomen. The diaphragm is completed at the ninth week by an ingrowth of muscle fibers from cervical myotomes into pleural and peritoneal folds. This coincides with the return of intestine from umbilical stalk.⁴ Congenital diaphragmatic hernia occurs when the muscular entities of the diaphragm fail to develop normally, resulting in displacement of abdominal components into the thorax. Bochdalek hernias make up the majority of cases. The major problem in Bochdalek hernias is posterolateral defects of the diaphragm, which results in either failure in the development of the pleuroperitoneal folds or improper or absent migration of the diaphragmatic musculature.⁵ Morgagni hernias are less common, occurring in only 5-10% of congenital diaphragmatic hernia cases. The foramen of Morgagni hernia occurs in the anterior midline through the sternocostal hiatus of the diaphragm.⁶

The late presentation of congenital diaphragmatic hernia was considered rare, but an increasing number of publications indicate that up to a quarter of patients are diagnosed after the neonatal period. Patients present with a wide variety of gastrointestinal and respiratory symptoms, but at least a quarter will be asymptomatic, and are often diagnosed incidentally.^{4,7} The diagnosis may be suspected clinically by the presence of bowel sounds in the lower hemithorax.⁸ Radiological appearances may resemble pneumatocele, pneumonia, pleural effusion, pneumothorax, pyopneumothorax and staphylococcal pneumonia.⁹ There is thoracic position of a nasogastric tube on a plain x-ray.⁸ Symptoms may be intermittent and mechanical factors including large meals, postoperative ileus, ileal loop, gastroenteritis, trauma, obesity, pregnancy and physical exertion which either

raise intra abdominal pressure or cause acute distension of abdominal viscera, may precipitate herniation and onset of symptoms. Acute presentation is usually due to incarceration, obstruction or strangulation of the hernia.⁴

Adult diaphragmatic hernias are most commonly repaired with simple suturing or mesh repair depending on the size of the defect. Mesh repair in a contaminated area is not recommended but it can be attempted provided there is coverage with a well vascularized tissue.¹⁰ Thoracotomy approach has the advantage of easier repair of the defect while laparotomy allows easier dealing with incarcerated viscera that may require resection.² In our case, we repaired both the defects via laparotomy.

A delayed presentation of congenital diaphragmatic hernia is uncommon but not rare. The features of these hernias are extremely varied and may be associated with misleading clinical and radiologic assessments leading to misguided therapy and a potentially fatal outcome. A high index of suspicion will avoid such circumstances.

REFERENCES

1. Ravitch MM. Congenital diaphragmatic hernia in Nyhus. In: *Hernia*. London: Pitman Medical Publishing; 1962. p. 527-5.
2. Islah MA, Jiffre D. A rare case of incarcerated bochdalek diaphragmatic hernia in a pregnant lady. *Med J Malaysia*. 2010 Mar;65(1):75-6.
3. Kissane JM, Smith MG. Posterolateral diaphragmatic hernia. In: *Pathology of Infancy and Childhood*. St Louis: C.V. Mosby; 1967. p. 508-9.
4. Heaton ND, Adam G, Howard ER. The late presentation of postero-lateral congenital diaphragmatic hernias. *Postgrad Med J*. 1992 Jun;68(800):445-8.
5. Rees JR, Redo SF, Tanner DW. Bochdalek's hernia. A review of twenty-one cases. *Am J Surg*. 1975 Mar;129(3):259-61.
6. Mandell GA, Finkelstein MS, Hallowell M. Delayed presentation of a symptomatic Morgagni hernia. *South Med J*. 1989 Oct;82(10):1299-302.
7. Ketonen P, Mattila SP, Harjola PT, Järvinen A, Mattila T. Congenital posterolateral diaphragmatic hernia in the adult. *Acta Chir Scand*. 1975;141(7):628-32.
8. Bağcı M, Dorobisz U. Late-presenting congenital diaphragmatic hernia in children: a literature review. *Pediatr Radiol*. 2005 May;35(5):478-88.
9. Lynch JM, Adkins JC, Wiener ES. Incarcerated congenital diaphragmatic hernias with bowel obstruction (Bochdalek). *J Pediatr Surg*. 1982 Oct;17(5):537-40.
10. Bulic K, Dzepina I, Mijatovic D, Unusic J. Prosthetic mesh for infected abdominal wall defects? Report of a patient with a large full thickness abdominal wall defect and colostomy due to a gunshot wound. *J Plast Reconstr Aesthet Surg*. 2008;61(4):455-8.